ATATÜRK ÜNİVERSİTESİ YAYINLARI
ATATURK UNIVERSITY PUBLICATIONS

Research Article *Araştırma Makalesi* DOI: 10.17567/currresdentsci.1764024

Impact of Maxillary Third Molars on the Anatomical Position of the Foramen Palatinum Majus: A CBCT Study

Üst Çene Üçüncü Azı Dişlerinin Foramen Palatinum Majus'un Anatomik Konumuna Etkisi: Bir CBCT Çalışması

Fatma YÜCE[1]
[1]İstanbul Kent University, Faculty of Dentistry, Dentomaxillofacial Radiology, İstanbul, Türkiye

Lorin CEMİLOĞLU[2]
[2]İstanbul Okan University, Faculty of Dentistry, Department of Endodontics, İstanbul, Türkiye

ABSTRACT

Objective: This study aimed to evaluate the effect of the presence or absence of maxillary third molars on the localization and morphometric features of the foramen palatinum majus (FPM) using cone-beam computed tomography (CBCT).

Methods: A retrospective analysis was conducted on CBCT scans of 250 individuals (139 males, 111 females) aged 20 to 80 years. Morphological characteristics and anatomical measurements of the FPM—including shape, location relative to adjacent teeth, and distances to the midpalatal suture, incisive foramen, and alveolar crest—were evaluated. Statistical analyses were performed using IBM SPSS Statistics v29.0. Statistical analyses were performed using chi-square tests for categorical and t-test/ANOVA for continuous variables.

Results: The FPM was most located between the distal aspect of the 7th molar and the mesial aspect of the third molar. In the absence of the third molar, the FPM shifted significantly posteriorly (*P*<.001). The shape of the FPM was predominantly anteroposterior, with significant right-left symmetry (*P<.001).* Aging was also associated with a posterior shift in FPM localization (*P*<.05). No significant differences were found in FPM shape according to sex or third molar presence.

Conclusion: The presence of maxillary third molars significantly influences the anatomical localization of the FPM. The findings support the use of CBCT as a reliable method for preoperative planning in palatal surgeries and local anesthesia procedures, facilitating anatomically guided, individualized approaches.

Keywords: Cone-beam computed tomography, foramen palatinum majus, maxillary third molars.

ÖZ

Amaç: Bu çalışma, konik ışınlı bilgisayarlı tomografi (CBCT) kullanarak maksiller üçüncü azı dişlerinin varlığının veya yokluğunun foramen palatinum majus'un (FPM) lokalizasyonu ve morfometrik özellikleri üzerindeki etkisini değerlendirmeyi amaçlamıştır.

Yöntemler: 20 ila 80 yaş arası 250 bireyin (139 erkek, 111 kadın) CBCT taramaları üzerinde retrospektif bir analiz yapılmıştır. FPM'nin morfolojik özellikleri ve anatomik ölçümleri (şekil, komşu dişlere göre konum ve orta damak sütürüne, kesici foramen'e ve alveolar krest'e olan mesafeler dahil) değerlendirilmiştir. İstatistiksel analizler IBM SPSS Statistics v29.0 kullanılarak yapılmıştır. İstatistiksel analizler kategorik değişkenler için ki-kare testi ve sürekli değişkenler için t-testi/ANOVA kullanılarak yapılmıştır.

Bulgular: FPM en çok 7. azı dişinin distal kısmı ile 3. azı dişinin mezial kısmı arasında yer almıştır. Üçüncü azı dişinin yokluğunda, FPM önemli ölçüde posteriora doğru kaymıştır (*P*<,001). FPM'nin şekli ağırlıklı olarak anteroposterior olup, önemli sağ-sol simetriye sahipti (*P*<,001). Yaşlanma da FPM lokalizasyonunda posteriora doğru bir kayma ile ilişkilendirilmiştir (*P*<,05). Cinsiyete veya üçüncü azı dişinin varlığına göre FPM şeklinde anlamlı bir fark bulunmamıştır.

Sonuç: Maksiller üçüncü azı dişlerinin varlığı, FPM'nin anatomik lokalizasyonunu önemli ölçüde etkiler. Bulgular, anatomik olarak yönlendirilmiş, bireyselleştirilmiş yaklaşımları kolaylaştırarak, palatal cerrahilerde ve lokal anestezi işlemlerinde ameliyat öncesi planlama için güvenilir bir yöntem olarak CBCT kullanımını desteklemektedir.

Anahtar Kelimeler: Konik ışınlı bilgisayarlı tomografi, foramen palatinum majus, maksiller üçüncü azı dişleri.

Geliş Tarihi/Received 13.08.2025
Revizyon Talebi/Revision Requested 23.10.2025
Son Revizyon/Last Revision 25.11.2025
Kabul Tarihi/Accepted 12.12.2025
Yayın Tarihi/Publication Date 26.08.2026

Sorumlu Yazar/Corresponding author: Fatma Yüce
E-mail: dtfatmayuce@gmail.com

Cite this article: Yuce F, Cemiloğlu L. Impact of Maxillary Third Molars on the Anatomical Position of the Foramen Palatinum Majus: A CBCT Study. *Curr Res Dent Sci.* 2026; 36(4):329-333. doi:10.17567/currresdentsci.1764024

Content of this journal is licensed under a Creative Commons Attribution-NonCommercial-NoDerivatives 4.0 International Licens

INTRODUCTION

The foramen palatinum majus (FPM) is a fissural opening located anatomically posterior to the hard palate, between the horizontal lamina of the palatine bone and the palatine process of the maxilla.[1] FPM is of clinical importance in terms of both dental anesthesia practices and surgical operations, as it is the passageway of the greater palatine nerve and vessels that open into the oral cavity. It may vary in terms of structure, size, and location among individuals. These variations may be affected by demographic and anatomical factors such as age, gender, dental status, and ethnicity. The clear localization of FPM, which is often described as an oval-shaped or anteroposteriorly extending foramen, plays a critical role, especially in maxillary nerve anesthesia and in planning the areas where soft tissue grafts will be taken.[2-4]

Traditional anatomical dissections, dry skull studies, and two-dimensional radiographs have long been used to determine the anatomical localization of FPM.[5-7] However, it has been reported that these methods are insufficient for detailed morphometric analyses due to limitations such as superposition, magnification, and distortion. Recently, with the widespread use of 3D imaging techniques such as cone beam computed tomography (CBCT), the morphological and positional features of the FPM can be evaluated more precisely.[8] CBCT has become a prominent method in dentomaxillofacial analyses because it enables the imaging of structures with axial orientation, such as the FPM, and offers reconstruction opportunities.

In the literature, the localization of the FPM and reference anatomical landmarks such as the 7th molar, third molar, incisive foramen, and midpalatal suture has been investigated in many studies.[3,9,10] However, in these studies, the relationships related to the 7th molar have generally been prioritized, and the effect of the third molar on the FPM has not been sufficiently focused on. In a few studies using CBCT technology, it has been reported that the localization of the FPM varies by ethnic group, age group, and tooth presence. In this context, examining the effects of the presence or absence of third molars on the morphometric characteristics of FPM will both contribute to anatomical knowledge and constitute an important reference for clinical applications.

Although various parameters have been examined in studies on FPM, no research has examined the relationship between third molars alone and FPM. The aim of this study is to evaluate the effect of the presence or absence of third molars on the localization and shape of FPM using CBCT images

METHODS

Study Design and Sample

In this retrospective study, CBCT images obtained for various diagnostic purposes between 2018 and 2023 from the archives of the Department of Dentomaxillofacial Radiology, Faculty of Dentistry, Istanbul Okan University, were evaluated. The study was conducted with the approval of the relevant Istanbul Okan University Ethics Committee (Date: January 10, 2024, Decision number 172/24). Inclusion criteria were individuals aged 18 years and over, skeletally developed, CBCT sections covering the upper jaw (13x5 cm FOV with 0.2x0.2x0.2 mm voxel size, 23x17 cm FOV with 0.4x0.4x0.4 mm voxel size), and with sufficient image quality. Coronal sections were evaluated with a reconstructed slice thickness of 0.4 mm.

Exclusion criteria included those with a history of maxillofacial trauma or surgery, the presence of cysts/tumors in the maxilla, congenital craniofacial anomalies, third molars with unclosed root apex, and images with incomplete protocols. In addition, the third upper molar was included in the study if it was fully erupted or absent; partially erupted or impacted teeth were excluded. CBCT data of a total of 250 eligible individuals (139 males, 111 females) were analyzed.

Imaging Protocol and Measurement Method

Images were obtained with the Planmeca ProMax (Planmeca, Helsinki, Finland) device at 96 kVp, 5.6 mA, 12 seconds, and analyzed with Romexis software (v4.6.1.R). All measurements were performed by a single observer (L.C.) on a medical monitor and in a dark room.

Our choice of CBCT-based landmarks and distances follows prior CBCT morphometric syntheses and clinically oriented guidance on the palatal region, ensuring reproducibility and clinical translatability.[8-10, 17] The following morphometric measurements were made for both sides (right-left) of the FPM:

1. Shape Evaluation: In axial sections, the FPM was classified as round or anteroposteriorly extending (Figure 1a).

2. Localization: The location of the FPM relative to the palatal regions of the 7th and/or 8th teeth was recorded by dividing it into five different categories;

1. localization: Foramen located palatal to tooth number 7

2. localization: Foramen located distopalatine of tooth number 7 and mesiopalatine of tooth number 8

3. localization: Foramen located palatal to tooth number 8

4. localization: Foramen located distopalatine of tooth number 8

5. localization: Foramen located distopalatine of tooth number 7 when tooth number 8 is absent

3. Distance Measurements:

- Distance between FPM and incisive foramen (Figure 1b)
- Distance between FPM and midline (midpalatal suture) (Figure 1c)
- Distance between centers of right and left FPM (Figure 1d)
- Vertical distance between FPM and alveolar crest peak (Figure 2).

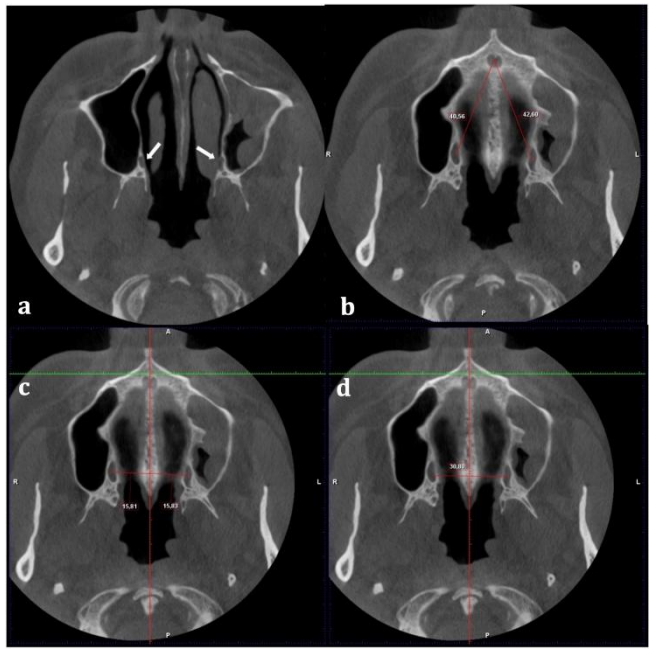

Figure 1. Examples of the shape of the FPM (white arrow on the a) and the measurements of the incisive foramen (b), midpalatal suture (c), and the distance between the two FPMs (d).

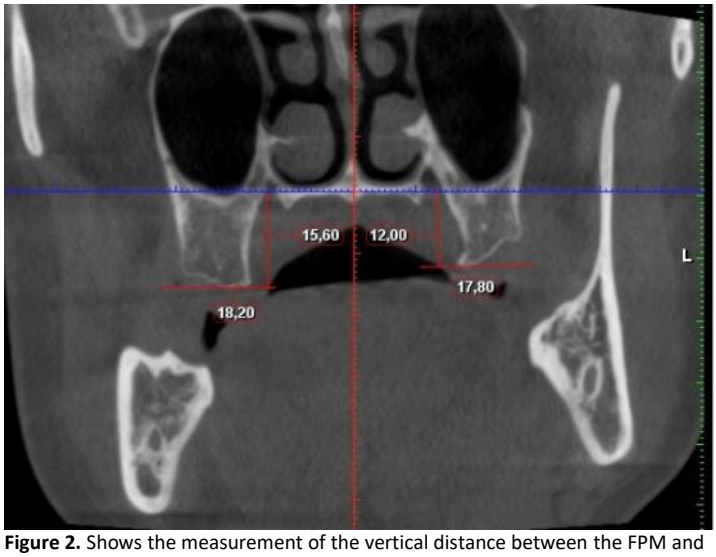

Figure 2. Shows the measurement of the vertical distance between the FPM and the alveolar crest peak in coronal sections.

Statistical Analysis

Statistical evaluation was performed in IBM SPSS Statistics 29.0 (IBM SPSS Corp., Armonk, NY, USA). Normality was assessed with the Kolmogorov–Smirnov test. Continuous morphometric distances are summarized as mean±SD, median, and range, and categorical variables as n (%); two-tailed α=0.05.

Hypothesis testing was limited to categorical outcomes related to FPM morphology and localization. FPM shape (round vs anteroposterior) and FPM localization categories were compared across study groups (e.g., third-molar presence vs absence) using Pearson's chi-square; for 2×2 tables, a continuity correction (Yates) was applied where appropriate. Linear distance measures (mm) from the FPM to reference landmarks were not subjected to between-group hypothesis testing. These measurements are tabulated descriptively.

RESULTS

In this study, the effects of the presence of third maxillary molars on FPM localization and morphometric features were evaluated through CBCT images of 250 individuals. The main findings obtained are summarized below:

Demographic Distributions

According to the study criteria, the average age of the individuals included in the evaluation was 48.38 (min. 20-max. 80); the gender distribution of the participants was 139 males (55.6%) and 111 females (44.4%) (Table 1).

• A total of 500 right and left maxillary third molar regions were examined; right maxillary molars were present in 76 regions and absent in 174 regions. The left maxillary molar tooth was present in 77 regions and absent in 173 regions (Table 1).

Shape of FPM

• The shape of the FPM was predominantly anteroposterior (88.8%), with 82.4% of right FPMs and 6.4% of left FPMs observed as round (Table 2).

• A significant symmetry was detected between the right and left FPM shapes (*P*<.001).

• Gender or the presence of a third molar did not show a significant effect on the FPM shape.

Table 1. Demographic distribution of the study population by sex and the presence or absence of maxillary third molars in the right and left posterior regions.

		Sex	Number of Individuals	Percentage (%)	
		Female	111	44.4	
		Male	139	55.6	
Third Molar Presence			Present	Absent	Total
		Right	76	174	250
		Left	77	173	250
		Total	153	347	

Table 2. The crosstab shows the relationship between right and left FPM (numbers are given in n).

		Left FPM Shape		
Right FPM Shape		Anteroposterior	Round	Total
	Anteroposterior	206 (82.4 %)	17 (6.8%)	223 (89.2%)
	Round	16 (6.4 %)	11 (4.4%)	27 (10.8%)
	Total	222 (88.8 %)	28 (11.2%)	250 (100%)
	Pearson χ^2 = 34.48, *P*<.001			

Localizations of FPM

On the right side, the localization of the FPM was as follows: in 17.6% of cases, it was located palatal to the 7th tooth; in 62.8%, it was positioned between the disto-palatal aspect of the 7th tooth and the mesio-palatal aspect of the 8th tooth; in 3.2%, it was palatal to the 8th tooth; in 7.6%, it was at the disto-palatal aspect of the 8th tooth; and in 8.8% of cases where the 8th tooth was absent, the FPM was found to be more posterior than the disto-palatal aspect of the 7th tooth (Figure 3).

On the left side, the distribution was similar: 16.8% of FPMs were located palatal to the 7th tooth; 60.8% were between the disto-palatal of the 7th and mesio-palatal of the 8th tooth; 7.2% were palatal to the 8th tooth; 6.4% were at the 8th tooth's disto-palatal aspect; and in 8.8% of cases without an 8th tooth, the FPM was located posterior to the disto-palatal aspect of the 7th tooth. The distribution of FPM localizations across sides is illustrated in the Figure (Figure 3).

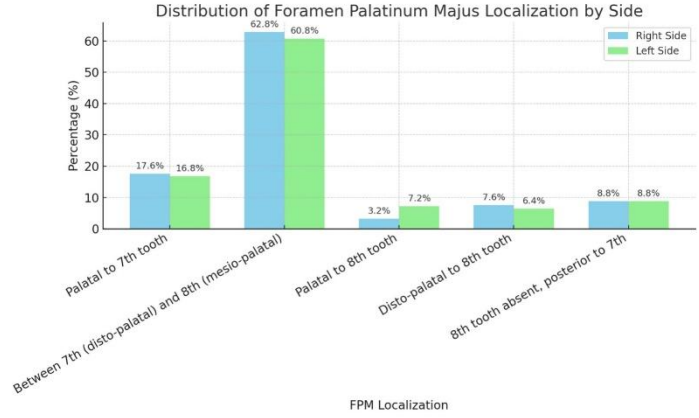

Figure 3. Percentage distribution of the FPM localization relative to adjacent molar teeth on the right and left sides. The most common position was between the disto-palatal aspect of the 7th tooth and the mesio-palatal aspect of the 8th tooth on both sides.

FPM was most frequently localized between the distopalatine of the 7th tooth and the mesiopalatine of the 8th tooth (62.8% on the right, 60.8% on the left).

The presence of the third molar tooth provided a more anterior location of the FPM, while its absence caused the FPM to shift significantly posteriorly (Pearson χ^2 = 40.88 and *P*<.001 for the right; Pearson χ^2 = 18.96 and *P*<.001 for the left) (Table 3).

A significant posterior shift in the location of the FPM was observed with increasing age (*P*=.013 for the right; *P*=.002 for the left).

Morphometric Measurements

The distances (in mm) of the FPM to the reference anatomical structures are given in detail in Table 4.

Table 3. Association between third-molar presence and anterior/posterior FPM localization. Localization was dichotomized by clinical landmarks: anterior = palatal to tooth 7 and between teeth 7–8; posterior = palatal to tooth 8 and distal to tooth 8.

Side	Third Molar	Anterior n (%)	Posterior n (%)	
Right	Present (n=76)	48 (63.2)	28 (36.8)	χ^2: 40.88 *P*<.001
	Absent (n=174)	36 (20.7)	138 (79.3)	
Left	Present (n=77)	31 (40.3)	46 (59.7)	χ^2: 18.96 *P*<.001
	Absent (n=173)	25 (14.5)	148 (85.5)	

Table 4. Shows left and right FPM measurement statistics; all values are in millimeters (mm).

Measurement		Mean	Median	SD	Min	Max
Right FPM	Midline	16.49	16.40	1.43	11.61	20.40
	Incisive Foramen	38.90	38.92	2.32	30.23	44.38
	Alveolar Ridge	10.17	10.20	2.61	3.90	17.20
Left FPM	Midline	16.14	16.20	1.53	11.20	20.60
	Incisive Foramen	39.04	39.22	2.26	32.20	45.97
	Alveolar Ridge	10.11	10.00	2.54	4.20	18.60
Distance between Right–Left FPM		32.87	32.66	2.64	25.80	40.60
SD: Standard Deviation						

DISCUSSION

FPM is a critical anatomical structure through which neurovascular bundles pass, making its precise localization essential in maxillofacial surgical and anesthetic procedures. In this CBCT-based study, we evaluated the localization and morphometric characteristics of FPM in relation to the presence or absence of third maxillary molars. Our findings indicate that the localization of FPM shifts significantly posteriorly in the absence of third molars, underscoring the importance of considering third molar status in clinical planning.

Previous studies have reported conflicting results regarding the typical anatomical location of the FPM. While some authors suggest a frequent localization palatal or distopalatal to the 7th molar,[8] others have identified a position palatal to the third molar.[11–13] In our study, the majority of FPMs (over 60%) were observed between the distopalatal aspect of the 7th molar and the mesio-palatal aspect of the third molar. This finding highlights a nuanced yet significant anatomical shift associated with the presence or absence of the third molar, a factor largely overlooked in prior anatomical analyses.

Another key observation was the posterior displacement of the FPM with increasing age. This result aligns with the findings of Comerdov *et al.*[14] and may be attributed to physiological changes in the maxillary bone, such as resorption and reduced alveolar bone height, which are commonly seen in older individuals. These findings emphasize the need for age-specific considerations during surgical interventions involving the palatal region.

In terms of morphometric parameters, our study revealed that the FPM is predominantly anteroposteriorly oriented and bilaterally symmetrical. Neither gender nor the presence of third molars had a statistically significant impact on the foramen's shape, suggesting that FPM shape is relatively constant among individuals. This bilateral symmetry supports the validity of using contralateral anatomical references during surgical planning, as also implied in previous studies.[14]

The distances measured between FPM and neighboring anatomical landmarks such as the midpalatal suture, incisive foramen, and alveolar crest were generally consistent with previous CBCT-based findings by Wang *et al.*[11] However, discrepancies with cadaveric studies such as those by Ashwini *et al.*[15] may be due to methodological differences (in vivo vs. ex vivo analysis) and potential ethnic variability. The average distance of 10 mm between the FPM and the alveolar crest was consistent with the 7–17 mm range reported by Klosek *et al.*[16] and may serve as a clinically useful reference for the application of local anesthesia in dentate individuals.

Notably, this study is among the few investigations that specifically analyze the influence of third molar presence on FPM localization using CBCT. Although studies like Comerdov *et al.*[14] have explored gender-based differences in FPM morphology, the effect of dentition status, particularly third molars, has rarely been addressed. Therefore, our research fills an important gap by offering both morphometric and clinical insights into FPM variability.

A methodological strength of this study is the use of CBCT, which offers superior spatial resolution and three-dimensional visualization while reducing radiation exposure compared with conventional imaging techniques. This imaging modality is well-suited for detailed morphometric studies of the dentomaxillofacial region, thereby improving measurement reliability.

Nevertheless, specific limitations must be recognized. The most important limitation of the study is the lack of information on whether third molars had been extracted previously or were developmentally absent (agenesis). Because extraction history and agenesis can influence palatal anatomy, their potential impact on FPM localization could not be assessed, thus limiting inferences regarding causality. The research was conducted at a single center with a geographically and ethnically homogeneous population, potentially limiting the generalizability of the results. The retrospective design limited the assessment of clinical parameters, including periodontal status and bone density, which may also affect FPM localization. Future research should adopt a multicenter, prospective design that incorporates diverse ethnic groups and comprehensive clinical evaluations. A comprehensive assessment of third molar characteristics, such as eruption angle and position, in relation to first permanent molars may enhance individualized surgical planning.

CONCLUSION

Our findings showed that the loss of the maxillary third molars significantly affects the location of the FPM and causes the foramen to shift posteriorly. Additionally, it was discovered that the FPM's morphology was primarily anteroposterior, with a high degree of symmetry between the left and right sides. The increasingly posterior position of the FPM with age likely reflects age-related changes in the maxillary bone. The findings are expected to support the development of tailored, anatomically informed clinical approaches for local anesthetic applications and surgical planning.

Ethics Committee Approval: This study was approved by the Istanbul Okan University Ethics Committee (Date: January 10, 2024, Decision number 172/24).

Informed Consent: Patient data were anonymized, and no identifying information was used. For this reason, informed consent was not required.

Peer-review: Externally peer-reviewed.
Author Contributions: Concept- F.Y., L.C.; Design – F.Y.; Supervision – F.Y.; Resources – F.Y., L.C.; Materials – F.Y.; Data Collection and/or Processing – L.C.; Analysis and/or Interpretation – F.Y., L.C.; Literature Search – L.C.; Writing Manuscript – L.C.; Critical Review – F.Y.
Data Availability Statement: The datasets generated and/or analyzed during the current study are available from the corresponding author upon reasonable request.
Conflict of Interest: The authors have no conflicts of interest to declare.
Financial Disclosure: The authors declare that they have no conflicts of interest.
Use of Artificial Intelligence: The study was conducted and prepared without the use of any artificial intelligence-assisted applications. Grammarly (Pro version) was used for language and grammar editing of this manuscript. The content, data analysis, interpretation, and scientific conclusions are entirely the work of the authors.

Etik Komite Onayı: Bu çalışma İstanbul Okan Üniversitesi Etik Kurulu tarafından onaylanmıştır (Tarih: 10.01.2024, Karar no: 172/24).
Hasta Onamı: Hasta verileri anonimleştirilmiş olup hiçbir tanımlayıcı bilgi kullanılmamıştır. Bu nedenle bilgilendirilmiş onam gerekli değildir.
Hakem Değerlendirmesi: Dış bağımsız.
Yazar Katkıları: Fikir- F.Y., L.C.; Tasarım – F.Y.; Denetim – F.Y.; Kaynaklar – F.Y., L.C.; Malzemeler – F.Y.; Veri Toplama ve/veya İşleme – L.C.; Analiz ve/veya Yorumlama – F.Y., L.C.; Literatür Taraması – L.C.; Makale Yazımı – L.C.; Eleştirel İnceleme – F.Y.
Veri Erişilebilirliği Beyanı: Bu çalışmada oluşturulan ve/veya analiz edilen veri setleri, makul bir talep üzerine ilgili yazardan temin edilebilir.
Çıkar Çatışması: Yazarlar, çıkar çatışması olmadığını beyan etmiştir.
Finansal Destek: Bu çalışma için herhangi bir dış finansman alınmamıştır.
Yapay Zeka Kullanımı: Çalışma, yapay zekâ destekli herhangi bir uygulama kullanılmadan yürütülmüş ve hazırlanmıştır. Çalışmanın dil ve gramer kontrolü için Grammarly (Pro sürümü) kullanılmıştır. Çalışmanın içeriği, veri analizi, yorumlanması ve bilimsel sonuçları tamamen yazarlar tarafından oluşturulmuştur.

REFERENCES

1. Erimoğlu C, Özbayrak T, Kökten G. Foramen palatinum majus ve canalis palatinus major'un anatoma-morfolojik varyasyonları. *J Istanbul Univ Fac Dent*. 1983;17(3-4):144-157.
2. Dere F. Anatomi Atlası ve Ders Kitabı. 5th ed. Adana: Nobel Tıp Kitabevi; 1999.
3. Mukhopadhyay P, Das S, Biswas S, Mukherjee P, Bhakta A. Morphological and morphometric study of greater palatine foramen in dry skulls of Eastern Indian population. *Natl J Clin Anat.* 2024;13(1):25-30.
4. Radošević D, Erić M, Marić D, et al. Morphology of the greater palatine foramen: a clinical point of view. *Surg Radiol Anat*. 2023;45(8):1001-1007.
5. Ajmani MJ. Anatomical variation in position of the greater palatine foramen in the adult human skull. *J Anat*. 1994;184:635-637.
6. Hassanali J, Mwaniki D. Palatal analysis and osteology of the hard palate of the Kenyan African skulls. *Anat Rec*. 1984;209(2):273-280.
7. Saralaya V, Nayak SR. The relative position of the greater palatine foramen in dry Indian skulls. *Singapore Med J*. 2007;48(12):1143-1146.
8. Rapado-González O, Suárez-Quintanilla JA, Suárez-Cunqueiro MM. Anatomical variations of the greater palatine canal in cone-beam computed tomography. *Surg Radiol Anat.* 2017; 39(7):717-723.
9. Kim DW, Tempski J, Surma J, et al. Anatomy of the greater palatine foramen and canal and their clinical significance in relation to the greater palatine artery: a systematic review and meta-analysis. *Surg Radiol Anat.* 2023;45(2):101-119.
10. Martins T, Guedes V, Martins E, Mesquita P. Morphometric analysis of the greater palatine foramen: a CBCT study in Portugal. *Surg Radiol Anat.* 2025;47(1):64.
11. Wang TM, Kuo KJ, Shih C, Ho LL, Liu JC. Assessment of the relative locations of the greater palatine foramen in adult Chinese skulls. *Acta Anat (Basel).* 1988;132(3):182-186.
12. Shalaby S, Eid EM, Sarg NAS, Sewilam AMA. Morphometric analysis of hard palate in Egyptian skulls. *Benha Med J*. 2015;32(1):59-72.
13. Varalakshmi KL, Sangeeta M. Anatomical study on location of greater palatine foramen in dried adult human skull: key to successful maxillary nerve block. *Int J Anat Res*. 2019;7(3.1):6762-6766.
14. Comerdov E. *Kanalis palatinus major, foramen palatinum majus ve çevresindeki yumuşak doku ile ilgili parametrelerin KIBT üzerinde değerlendirilmesi.* [Diş Hekimliğinde Uzmanlık Tezi]. Ankara: Hacettepe Üniversitesi; 2019.
15. Ashwini H, Jaishree H. The morphometric study of greater palatine foramen in dry adult skulls. *Indian J Med Case Rep*. 2014;3(4):73-77.
16. Song JE, Um YJ, Kim CS, et al. Thickness of posterior palatal masticatory mucosa: the use of computerized tomography. *J Periodontol*. 2008;79(3):406-412.
17. Klosek SK, Rungruang T. Anatomical study of the greater palatine artery and related structures of the palatal vault: considerations for palate as the subepithelial connective tissue graft donor site. *Surg Radiol Anat*. 2009;31(4):245-250.