

Investigation the angulation of maxillary impacted canines by using cone-beam computed tomography

Nihat Laçın¹, Mustafa Yalçın²

¹ Izmir Katip Çelebi University, Faculty of Dentistry, Department of Oral and Maxillofacial Surgery, Izmir, Turkey

² Istanbul Kent University, Faculty of Dentistry, Department of Oral and Maxillofacial Surgery, Istanbul, Turkey

Abstract

Aim: This study aimed to evaluate the angulation and localization of unilaterally impacted canines by using CBCT.

Methodology: Seventy-two images were included in the study based on the inclusion criteria. Demographic information (age and gender), localization and angulation of the impacted canine teeth were recorded. Canine angulation was measured between the two lines drawn on the coronal section of CBCT, with the first line drawn from the crista galli to the anterior nasal spine and the second line drawn along the long axes of the impacted canine teeth.

Results: The mean age was 35.42±12.29 years in men and 31.10±11.09 years in women. In women, 16 of the impacted canines were on the right and 23 were on the left side, while in men, 21 of them were on the right and 12 were on the left side. Mean angulation was 34.6° (range, 17.6° - 64.4°) for women and 36.2° (range, 21.4° - 56.3°) for men. A weak negative correlation was found between patient age and angulation ($p=0.49$, $\rho = -0.233$).

Conclusion: Angulation of maxillary impacted canines is an important predictive factor in orthodontic treatment. In the present study, no significant difference was found between angulation and canine localization and gender.

Keywords: impacted canine, angulation, maxilla, cone-beam computed tomography

Correspondence:

Dr. Mustafa YALÇIN

Istanbul Kent University, Faculty of Dentistry, Department of Oral and Maxillofacial Surgery, Istanbul, Turkey.
E-mail:myalcin.omfs@gmail.com

Received: 12 September 2021

Accepted: 25 March 2022

Access Online



DOI:

10.5577/intdentres.2022.vol12.no1.2

How to cite this article: Laçın N, Yalçın M. Investigation the angulation of maxillary impacted canines by using cone-beam computed tomography. Int Dent Res 2022;12(1):9-13. <https://doi.org/10.5577/intdentres.2022.vol12.no1.2>

Introduction

Maxillary canine teeth are the second most commonly impacted teeth after the third molars and often pose challenge for orthodontic treatment when they erupt into the dental arch. The incidence of canine impaction is 85% palatal and 15% buccal (1). Ericson and Kurol reported the incidence of impacted maxillary canines as 1.7% (2). Dachi and Howell

reported the incidence of unilateral and bilateral impacted maxillary canines as 92% and 8%, respectively (3). Impacted maxillary canines might lead to the growth of the dentoalveolar arch, recurrent infection, risk of follicular cyst formation, root resorption, adjacent teeth aesthetic problems, and occlusion problems (4-6).

Panoramic radiography is commonly used in dental procedures. However, this technique is not sufficient

for evaluating the exact position of the impacted teeth due to its two-dimensional imaging technology (7, 8). Three-dimensional imaging techniques such as cone-beam computed tomography (CBCT) are beneficial for orthodontic treatment and surgical intervention of palatally impacted maxillary canines and mandibular third molar teeth in relation to inferior alveolar canal.

There are various etiological factors leading to the impaction of maxillary canines, such as insufficient space in the dentoalveolar arch, ankylosis, cysts/tumors related to the unerupted canine, maxillary trauma, cleft lip and palate, supernumerary teeth, root dilacerations, excessive thickness of the soft tissue and of the bone covering the canine, and syndromes (9, 10). Treatment options of impacted maxillary canines include orthodontic and surgical techniques. Moreover, combinations of surgical and orthodontic treatments are also performed to bring the canines to the dental arch. A number of factors including the angulation and localization of the impacted canines, patient age, and the severity of the impaction are determinant factors for treatment protocol and affect the duration and success of the treatment. For this reason, evaluation of impacted canines by CBCT prior to treatment planning is critical for determining the ideal treatment protocol and for avoiding damage to the adjacent teeth and anatomical structures such as maxillary sinus and nasal cavity. In this study, we aimed to evaluate the angulation and localization of unilaterally impacted canines by using CBCT.

Materials and Methods

The retrospective study reviewed over 2,500 CBCT images, among which 72 images were included in the

study based on the inclusion criteria. The study was approved by Izmir Katip Celebi University Ethics Committee and the study protocol was conducted in accordance with the 1975 Helsinki Declaration as revised in 2000 (Approval number: 2020-733). Informed consent form was not obtained due to retrospective radiological study. The exclusion criteria were as follows: lack of demographic information, inadequate scan quality, extensive pathologic entity related to impacted canine teeth in the maxilla, age under 18 years, maxillofacial anomalies and/or syndromes, cleft lip and palate, orthodontic treatment of the impacted canine, and early tooth extraction.

All patients underwent CBCT scanning using a NewTom 5G CBCT machine (QR s.r.l., Verona, Italy), operating at 110 kVp and 1-20 mA, with a 15 × 12 field of view and standard resolution mode (voxel size 0.2 mm) in the supine position. The presence of impacted maxillary canines was detected on NNT station (QR srl, Verona, Italy) using the “zoom” tool and manipulation of brightness and contrast on a computer monitor (The RadiForce MX270W features a 27-inch large screen size and a 2560 × 1440 high-resolution) under dim lighting conditions.

Demographic information, localization and angulation of the impacted canine teeth were recorded. Canine angulation was measured between the two lines drawn on the coronal section of CBCT, with the first line drawn from the crista galli to the anterior nasal spine and the second line drawn along the long axes of the impacted canine teeth (line between canine cusp tip and apex) (Fig. 1). Intraoperator reliability for measurements that was performed by the same researcher was estimated using the intraclass correlation coefficient (ICC) with an interval of at least two weeks between them, which yielded a 94% agreement rate.

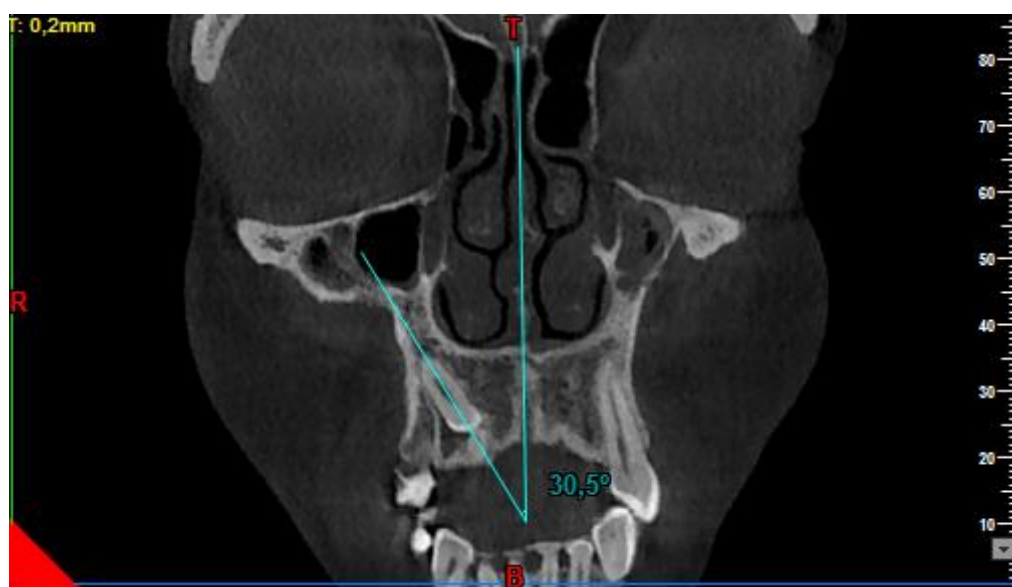


Figure 1. Measurement the angulation of maxillary impacted canines in the coronal section of CBCT

Statistical analysis

Data were analyzed using SPSS 25.0 (IBM SPSS Inc., Armonk, NY, USA). Normal distribution of data was determined using Kolmogorov-Smirnov test. The means of two independent groups were compared using Independent Samples t-test in data with normal distribution and using Wilcoxon signed-rank test in data with nonnormal distribution. In data with nonnormal distribution, correlations between two continuous variables were determined using Spearman's Correlation Coefficient. A p value of <0.05 was considered significant.

Results

The 72 patients included 39 (54.2%) women and 33 (45.8%) men with a mean age of 33.08±11.77 (range, 18-65) years. The mean age was 35.42±12.29 years in men and 31.10±11.09 years in women. In women, 16 of the impacted canines were on the right and 23 were on the left side, while in men, 21 of them were on the right and 12 were on the left side (Fig. 2). No significant difference was found between the localization of impacted canine (right, left) and gender (p=0.56).

Mean angulation was 34.6° (range, 17.6°-64.4°) for women and 36.2° (range, 21.4°-56.3°) for men and no significant difference was observed between men and women with regard to angulation (p=0.684), (Fig.3).

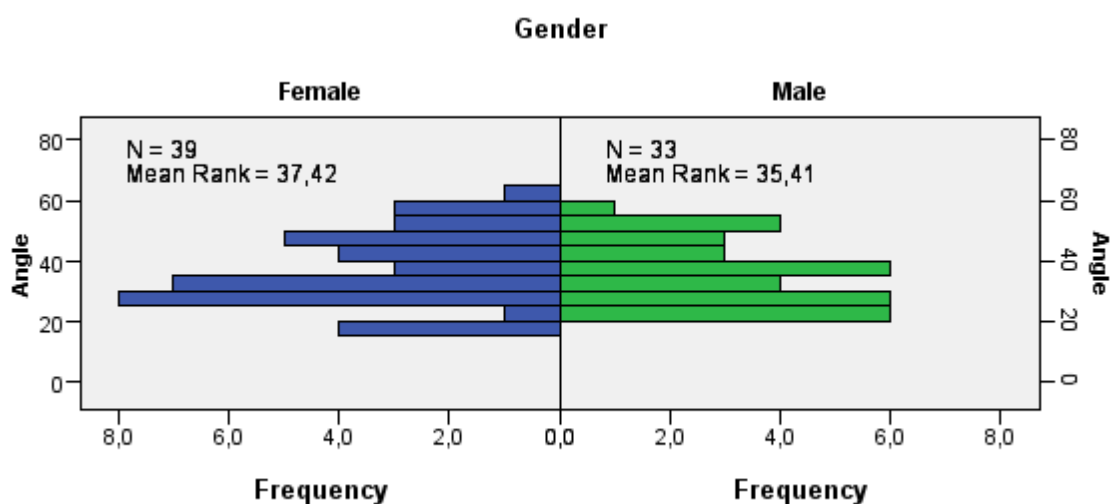


Figure 2. Distribution the angulation of maxillary impacted canines in female and male patients

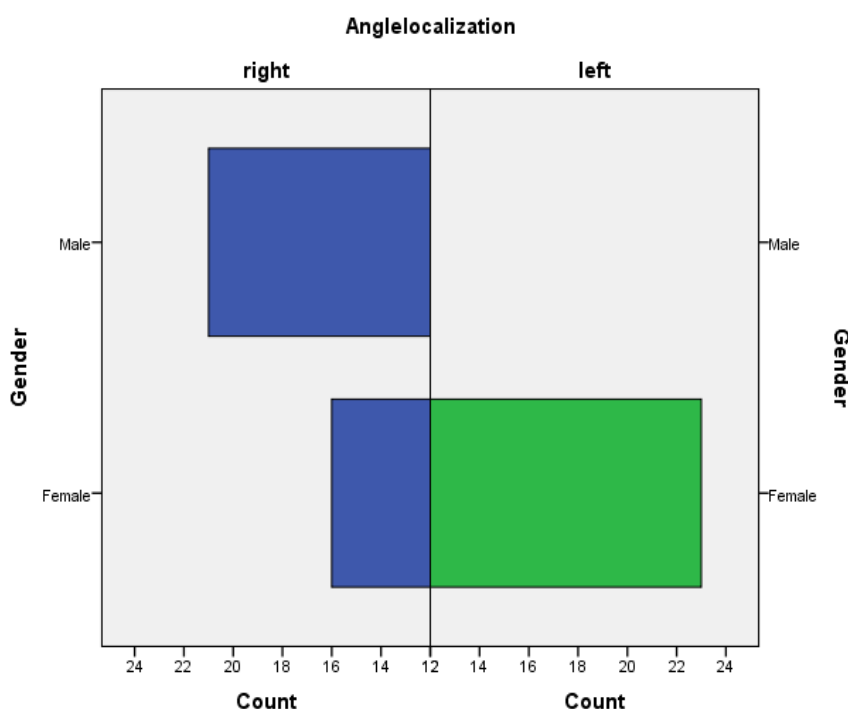


Figure 3. Distribution the angulation of maxillary impacted canines in female and male patients

Mean angulation was $35.36^\circ \pm 10.18^\circ$ in the right and $38.80^\circ \pm 12.45^\circ$ in the left side and no significant difference was found between the right and left sides with regard to angulation ($p=0.217$), (Fig. 2).

A weak negative correlation was found between patient age and angulation ($p=0.49$, $\rho = -0.233$), which indicates that the angulation decreased as the age increased (Fig. 4).

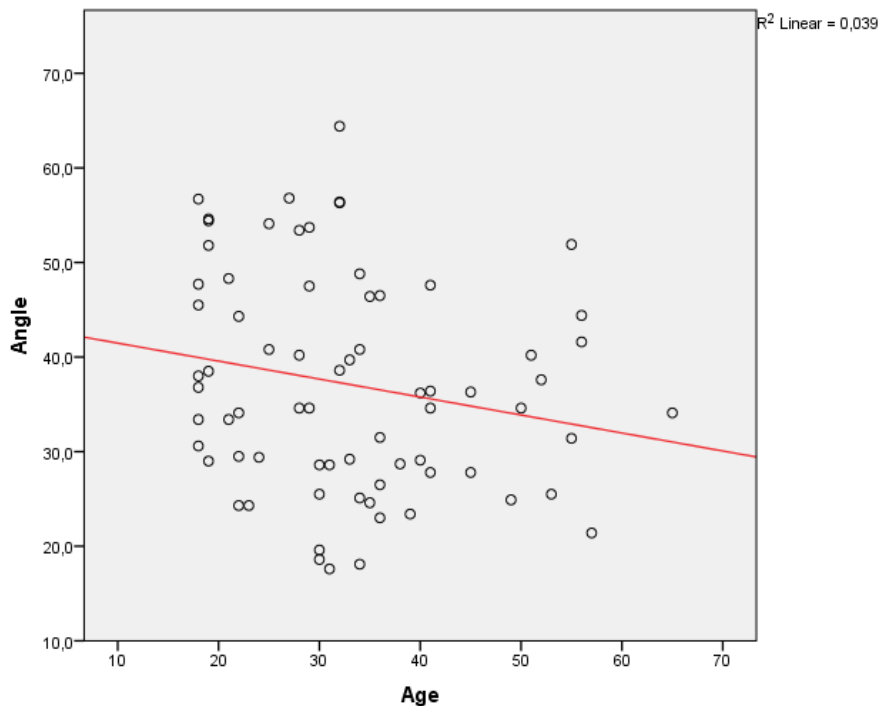


Figure 4. Distribution of the angulation according to age

Discussion

To date, various measurement techniques have been performed for the evaluation of the angulation of impacted maxillary canines by CBCT (11). The angular measurements on CBCT images include: i) the angle between the long axis of the canine and the midline of the maxilla in the coronal section, ii) the angle between the long axis of the lateral incisor and the canine in the coronal section, iii) the angle between the long axis of the canine and the occlusal plane in the sagittal section (11). In the present study, the midline of the maxilla was taken as a reference plane to determine the angulation of the canines.

Counihan et al. evaluated canine angulation based on the midline of the maxilla and found a negative correlation between the angle of the impacted canine and prognosis. Moreover, the authors defined the good prognosis as $0-15^\circ$, average prognosis as $16-30^\circ$, and poor prognosis as 31° and over (9). Bazargani et al. reported that the distance of the canine cusp to the occlusal plane increases and suggested that the impacted canine is positioned medially when the angulation degree of the impacted canine related to

the midline is higher. The authors also noted that the duration of treatment increases as the effect of angulation and the distances between the midline and the canine cusp tip and the occlusal plane. Additionally, the authors demonstrated that the duration of orthodontic treatment increases as the angulation of the impacted canine and the distance between the midline and the occlusal plane increases (12). Therefore, determination of the angulation prior to surgical exposure and orthodontic treatment is crucial for the duration and success rate of the treatment. In the present study, the mean angulation was 34.6° in women and 36.2° in men. This finding, according to the classification proposed by Counihan et al., indicates that the prognosis was poor in men and women within the limitation of the study (9). In our study, we only examined the adults who were over 18 years and thus future studies may investigate the angulation of impacted maxillary canines in patients under 18 years and may compare the outcomes with those of adults. In addition, our finding also revealed that gender and the localization of the canine had no significant effect on canine angulation. However, the canine angulation decreased with age although there was no strong relationship between age and angulation.

Besides the angulation of the impacted canine, Counihan et al. evaluated the prognosis of impacted maxillary canines according to the position of the canine root apex in the horizontal section, vertical height of the canine crown according to the cemento-enamel junction of the lateral incisor, and the degree of the impacted canine crown horizontally overlapping the neighboring incisor. The authors also noted that if the prognosis is estimated to be good based on the criteria mentioned above, an impacted canine may erupt spontaneously after extraction of the deciduous canine within one year, and if it does not erupt, surgical exposure and orthodontic alignment or surgical extraction can be performed (9).

Conclusions

Angulation of maxillary impacted canines is an important predictive factor in orthodontic treatment. In the present study, the mean angulation was 34.6° in women and 36.2° in men and no significant difference was found between angulation and canine localization and gender. Further studies are needed to compare young and adult patients.

Ethical Approval: Ethics committee approval was received for this study from İzmir Katip Çelebi University, Ethics Committee in accordance with the World Medical Association Declaration of Helsinki, with the approval number: 2020-733).

Peer-review: Externally peer-reviewed.

Author Contributions: Conception - N.L.; Design - M.Y., N.L.; Supervision - M.Y.; Materials - N.L., M.Y.; Data Collection and/or Processing - N.L., M.Y.; Analysis and/or Interpretation - N.L.; Literature Review - M.Y., N.L.; Writer - M.Y.; N.L.; Critical Review - M.Y.

Conflict of Interest: No conflict of interest was declared by the authors.

Financial Disclosure: The authors declared that this study has received no financial support.

References

1. Hitchen AD. The impacted maxillary canine. *Br Dent J* 1956; 100:1-14.
2. Ericson S, Kurol J. Radiographic assessment of maxillary canine eruption in children with clinical signs of eruption disturbances. *Eur J Orthod* 1986; 8(3):133-140. ([Crossref](#))
3. Dachi SF, Howell FV. A survey of 3,874 routine full-mouth radiographs. II. A study of impacted teeth. *Oral Surg Oral Med Oral Pathol* 1961; 14(10):1165-1169. ([Crossref](#))
4. Yan B, Sun Z, Fields H, Wang L. Maxillary Canine Impaction Increases Root Resorption Risk of Adjacent Teeth: A Problem of Physical Proximity. *Orthod Fr* 2015; 86(2):169-79. ([Crossref](#))
5. Bishara SE. Impacted maxillary canines: a review. *Am J Orthod Dentofacial Orthop* 1992; 101:159-71. ([Crossref](#))
6. Grisar K, Piccart F, Al-Rimawi AS, Basso I, Politis C, Jacobs R. Three-dimensional Position of Impacted Maxillary Canines: Prevalence, Associated Pathology and Introduction to a New Classification System. *Clin Exp Dent Res* 2019; 5(1):19-25. ([Crossref](#))
7. Malik DS, Fida M, Sukhia RH. Correlation between radiographic parameters for the prediction of palatally impacted maxillary canines. *J Orthod* 2019; 46(1):6-13. ([Crossref](#))
8. Haney E, Gansky SA, Lee JS, Johnson E, Maki K, Miller AJ, et al. Comparative analysis of traditional radiographs and cone-beam computed tomography volumetric images in the diagnosis and treatment planning of maxillary impacted canines. *Am J Orthod Dentofacial Orthop* 2010; 137:590-597. ([Crossref](#))
9. Counihan K, Al-Awadhi EA, Butler J. Guidelines for the assessment of the impacted maxillary canine. *Dent Update* 2013; 40(9):770-7. ([Crossref](#))
10. Chapokas AR, Almas K, Schincaglia GP. The Impacted Maxillary Canine: A Proposed Classification for Surgical Exposure. *Oral Surg Oral Med Oral Pathol Oral Radiol* 2012; 113(2):222-8. ([Crossref](#))
11. Alqerban A, Jacobs R, Fieuws S, Willems G. Radiographic predictors for maxillary canine impaction. *Am J Orthod Dentofacial Orthop* 2015; 147(3):345-54. ([Crossref](#))
12. Bazargani F, Magnuson A, Dolati A, Lennartsson B. Palatally Displaced Maxillary Canines: Factors Influencing Duration and Cost of Treatment. *Eur J Orthod* 2013; 35(3):310-6. ([Crossref](#))